

Periimplantitis and Er:YAG laser

Author_Dr Carole Leconte, France

Fig. 1 Periimplantitis is becoming increasingly prevalent.

Fig. 2 Initial appearance of the very shrunk mandible, major periimplantitis.

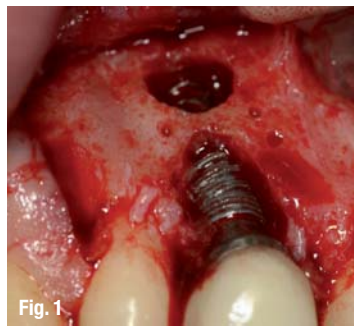
Fig. 3 Periodontal probe that is too short, pockets of more than 30 mm all around the implants.

Fig. 4 The first centimetre and even more is only granulation tissue, of differentiated, inflammatory, haemorrhagic appearance; it is very difficult to approach this type of site with a cold knife.

Fig. 5 Removal of the granulation tissue by Er:YAG laser, scaling without contact, without "leakage" of unsupported tissue, maintaining the healthy tissues and removing all the unsupported tissue down to the implant in the bone.

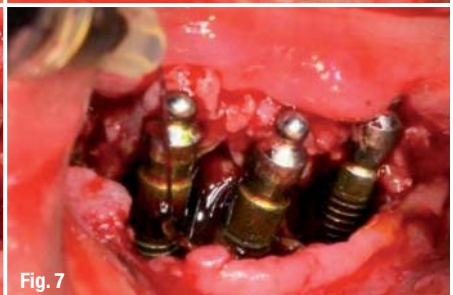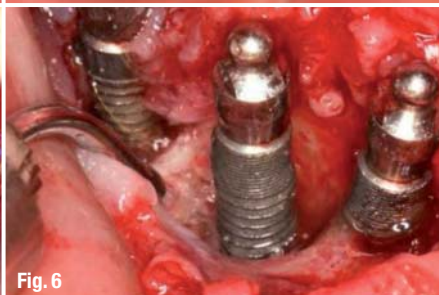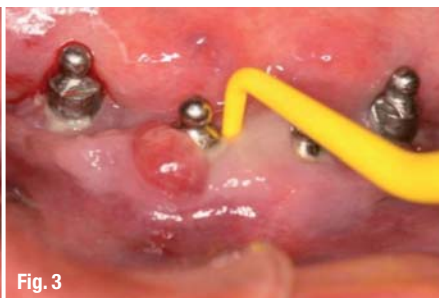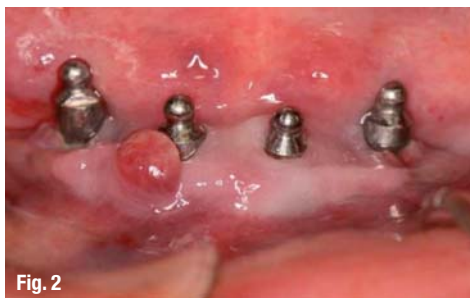Periimplantitis is becoming increasingly prevalent (Fig. 1). Its aetiologies are varied and often connected. Among the existing treatments, the Erbium:YAG laser is possibly the least known, despite its numerous clinical advantages. Those include the removal of granulation tissue and tartar and the decontamination of the titanium while, at the same time, conserving healthy tissue and existing implant structures. The first step in any treatment of periimplantitis is to carefully analyse the clinical situation in order to identify and remedy possible causes (hygiene, prostheses, lack of tissue etc.) and to evaluate whether the implants should be treated or removed.

Depending on the situation, a more favourable outcome might be achieved by removing the previous work rather than treating the current problem.



The removal would allow a tissue reconstruction which would provide the new treatment with better bases, thus making the final result more predictable.

However, there are numerous "conservative" treatments of periimplantitis possible, of which some are associated with tissue regeneration while others are not. In any instance, the aetiology must be identified, the pathological tissues removed and decontamination carried out. This is generally achieved by techniques of scaling (manual or ultrasonic), air polishing, photodynamic therapy¹ or local/general antibiotics.² It is highly recommended to inform the patient about the different treatment options and to actively involve him in the decision making as his willingness to cooperate is crucial to the course of the treatment. Particularly in cases of unexpected complications or sudden, necessary changes of

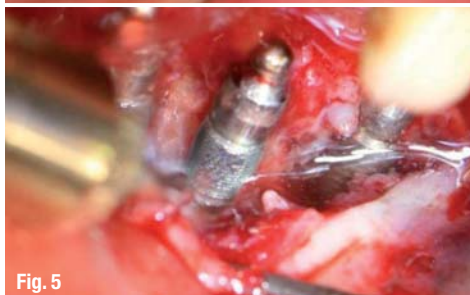
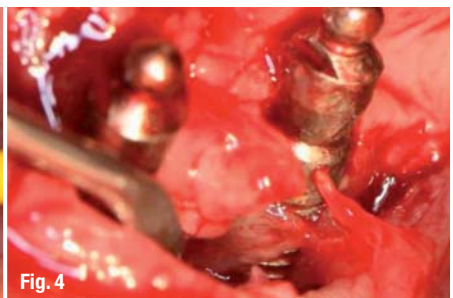
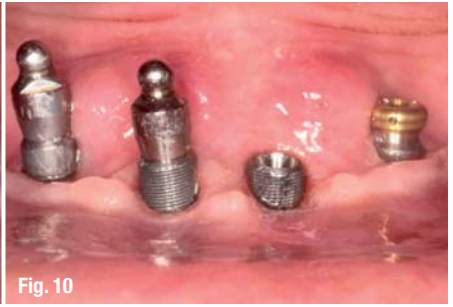
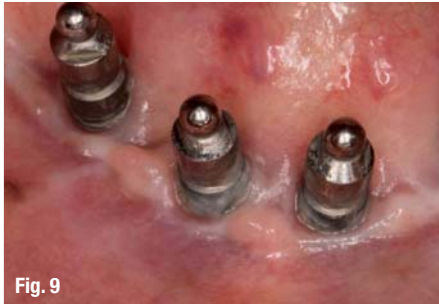
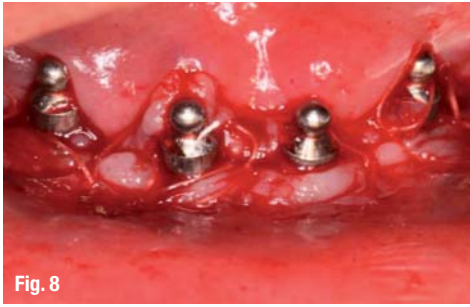

Fig. 6 Bone craters cleaned, implants decontaminated along the entire surface outside the bone.

Fig. 7 Three minutes betadine irrigation, then rinsing with saline solution.

Fig. 8 Sutures (no bone or other filling was carried out).

Fig. 9 Appearance of the tissues at one year of healing, maturation, absence of clinical relapse, organisation of keratinised tissue adhering around the implants, hygiene could be improved.

Fig. 10 Stage of change of attachment system (balls > locators) for the patient's comfort.

Figs. 11a & b Initial panoramic X-ray, global and detailed view with bone level highlighted.

Figs. 12a & b Visit after one year: apart from the external aspect that shows no sign of periimplantitis, the spontaneous bone regeneration that followed the debridement is considerable; the comparison of the two X-rays shows vertical bone gain and bone-titanium contact in this place.

treatment, the patient's initial say in the medical decisions might soften the impact of a different outcome. Having emphasised that there are other ways of treating periimplantitis than just following conservative treatment options, it is equally vital to stress that no matter what treatment is used it is very important to identify and adequately deal with the causes in order to ensure the best possible healing process.

There is no miracle instrument that guarantees a successful treatment of all types of periimplantitis. However, in those instances that include treatments of the gums, the bone, the pathological tissues and the titanium, the Er:YAG laser holds major advantages over other treatment options.

Bases for a better understanding

A laser is a photon beam with considerable energy. When emitted in very short pulses, the electromagnetic beam interacts with matter in a predictable way.

This interaction differs from that of traditional instruments that mostly follow Newton's laws of physics. When working with a laser, the laws of quantum physics guarantee a predictable effective-

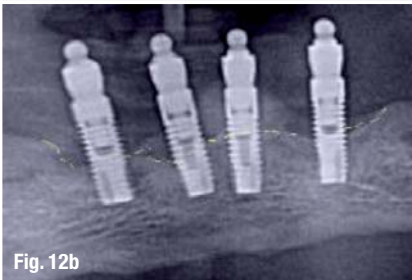
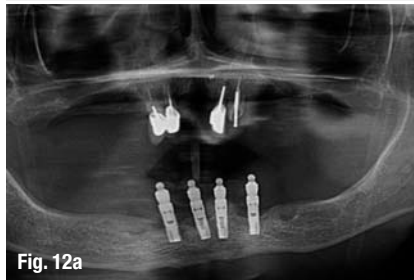
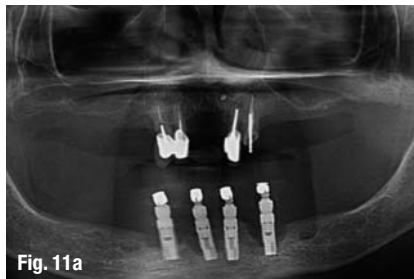
ness that can be parameterised in advance. The treatment is without any direct contact and the intensity applied depends on the methods of emission and application and on the tissue structure. Like sunlight that irradiates the surface of the earth, according to the season (distance), the time (angulation) and the matter (molecular nature/colour), the laser beam deviates, from the initial parameterisation. By varying and adjusting the intensity (power), the emission frequency (Hz), the distribution surface of the emitted energy and the parameters cited above (distance, angle etc.), the effects can be "controlled". The Er:YAG lasers have a 2,940 nm wavelength. The infrared (invisible) light is strongly absorbed by water and hydroxyapatite. This extreme absorption, which is caused by the photoablative effects, allows the precise and selective removal of pathological tissues and various deposits while leaving the healthy tissue untouched. It also provides a controlled bacterially detoxified surface.

The efficacy of the ablation is 540 µg/J and the depth of the removal by pulse is greater than 0.4 mm.³ Due to the extremely fine and translucent tips of the Er:YAG laser, it guarantees an optimal visual control while working without any direct contact. This makes it a particularly effective laser for several key stages of treatment of pathological peri-implant.

Removal of granulation tissue

The photoablative effects vaporise the matter and break into the granulation tissue, which in effect eases and lead to the complete elimination of the tissue. The applied method and precise parameter settings limit the iatrogenic nature of the scaling.

While using a round purr would have caused considerable damage with less ablative and greater thermal effect reducing visual control⁴⁻⁷, the penetration of the erbium laser is almost nil (less than 30 µ) and therefore no damage of the bone is done. Due to the precision of the work, the healthy tissues stay untouched. This is even more so the case when the instrument is supported by operating microscopes or high-power fibre magnifying glasses.



Removal of the tartar— decontamination of the titanium

This allows:

- Mucous membrane to be cleared off of the infiltrated area.
- The bone to be cleaned off granulation tissue and yet to be preserved, without aggression ("cold" laser) in order to avoid any necrotic halos, which can lead to complications or failures.
- To preserve the decontaminated titanium which can then, at a later point, be re-osseointegrated.

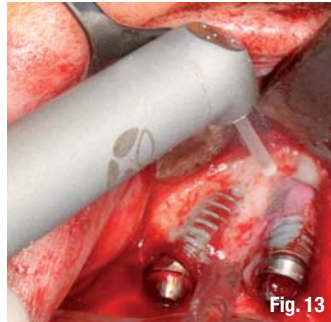


Fig. 13

periimplantitis. This may explain a certain reluctance towards the use of other instruments such as the Er:YAG laser. Each and every instrument is unique, in the same way as the characteristics of one laser can differ considerably from those of another. Each type of laser has very specific, sometimes even opposing effects. For instance, diode lasers do not damage the titanium but cause

a harmful temperature rise while Nd:YAG lasers will damage the surface of the titanium. With regards to the treatment of periimplantitis, the specific characteristics of the Erbium laser prove to be the most effective: it allows the operator to accurately select and precisely remove the pathological tissue and to decontaminate the titanium without staining it, hence enabling a renewed osseointegration. However, the successful treatment still depends on the individual practitioner and the employed equipment. Further research is needed to improve the procedure and predictability of the desired results. The world of implantology is constantly evolving and the revolution of the old implantological treatments lead to new developments and techniques. Facing those changes, dentists must actively seek and promote all available treatment options, including the use of laser. There is a very good reason for its growing presence.

Fig. 13 Laser devices have proven to be very effective in the treatment of periimplantitis.

Clinical case

In the present case, a 76-year-old patient visited our clinic and presented us with a poor initial situation indicating very poor dental hygiene, xerostomia, oral thrush, a poorly adapted prosthesis, non-passive, no vestibule. The patient's first visit to our clinic was in July 2010, although the symptoms of a periimplantitis had already been developing since 2004. A non-conservative treatment, including the removal of the implants and scaling, secondary reconstruction of bone and keratinised mucous membrane if necessary (Figs. 1–12) seemed favourable. However, the particular circumstances of the patient's poor dental health, partially caused by problems with alimentation leaving the patient fragile, led us to try to conserve the highly infected implants, which had peri-implant pockets of over 13 mm wide.

Conclusion

There is a multitude of traditional instruments such as curesttes, specific ultrasound inserts and titanium brushes that are commonly used when treating

contact

Dr Carole Leconte

14 rue du Croissant
75002 Paris
Tel.: + 33 01 53890311
cabinet@drleconte.cab

Kurz & bündig

Dieser Artikel beschreibt die Vorteile des Er:YAG-Laser-Einsatzes bei der Behandlung von Periimplantitis. Neben den konventionellen Therapiemöglichkeiten, wie spezielle Ultraschalleinsätze oder Titanbürsten, kann die Nutzung eines Er:YAG-Lasers dabei besonders im Bereich des Zahnfleisches, der Knochen, des krankhaften Gewebes und des Titans von Vorteil sein.

Der Er:YAG-Laser hat eine Wellenlänge von 2.940 nm. Der unsichtbare Infrarot-Lichtstrahl wird stark von Wasser und Hydroxylapatit absorbiert. Diese enorme Aufnahme, die durch photoablativ Effekte verursacht wird, ermöglicht das präzise und selektive Entfernen von pathologischem Gewebe, während das gesunde Gewebe unberührt bleibt. Aufgrund der sehr feinen und lichtdurchlässigen Spitze des Lasers, ist eine sehr gute Sichtkontrolle während der Arbeit ohne direkten Kontakt möglich. Das macht den Laser für mehrere wichtige Behandlungsphasen im pathologischen periimplantären Bereich attraktiv. Dennoch sind Laser je nach Wirkung einzusetzen, denn diese sind spezifisch und können sogar gegensätzliche Wirkungen haben. Diodenlaser beispielsweise schaden Titan zwar nicht, verursachen aber einen erheblichen Temperaturanstieg, Nd:YAG-Laser können sogar die Titanoberfläche zerstören. Der Einsatz eines Er:YAG-Lasers gestaltet sich daher am effektivsten, da der Bediener exakt auswählen, das krankhafte Gewebe entfernen und das Titan dekontaminieren kann und somit eine erneute Osseointegration ermöglicht wird.