

Laser assisted crown-lengthening in the anterior maxilla

Author_Minovska Ana, Cvetanovska Stojcheva Daniela, Macedonia

The harmonious and aesthetic appearance of the anterior maxillary region of the mouth has great impact on improving patients' physical appearance and hence their self-esteem. It is no longer enough to simply reproduce lost tooth structure. Contemporary standards emphasise the importance of avoiding procedures that will result in aesthetic compromise, as the aim is to provide patients with improved aesthetics whenever possible.

Among the most frequently used methods to achieve predictable, successful aesthetic rehabilitation of the smile is crown lengthening. Crown lengthening entails a surgical procedure performed by a dentist to expose a greater amount of tooth structure for the purpose of subsequently restoring the tooth prosthetically.¹ The procedure exposes more of the natural tooth by reshaping or recontouring the bone and the gingival line. This treatment can be performed on a single tooth, multiple teeth or the entire gingival line to

achieve a pleasant, aesthetically pleasing smile. When performed in the anterior maxillary region, its purpose is to facilitate an ideal gingival architecture, which involves recontouring of the hard and soft tissue in order to prevent violation of the biologic width.^{2,3}

Since the maintenance of a healthy periodontium remains the sine qua non of a successful aesthetic and functional restoration, it is essential not to interfere with the normal arrangement or functioning of the biologic width. Because the biologic width appears to constitute a constant feature in the human periodontium, it has been suggested as an inviolate therapeutic parameter.⁴ Clinical observation indicates that impingement of the biologic width will result in attempts by the gingival tissue to re-establish its original dimension through bone resorption or, in the presence of a thick alveolar crest, chronic gingival inflammation.^{5,6}

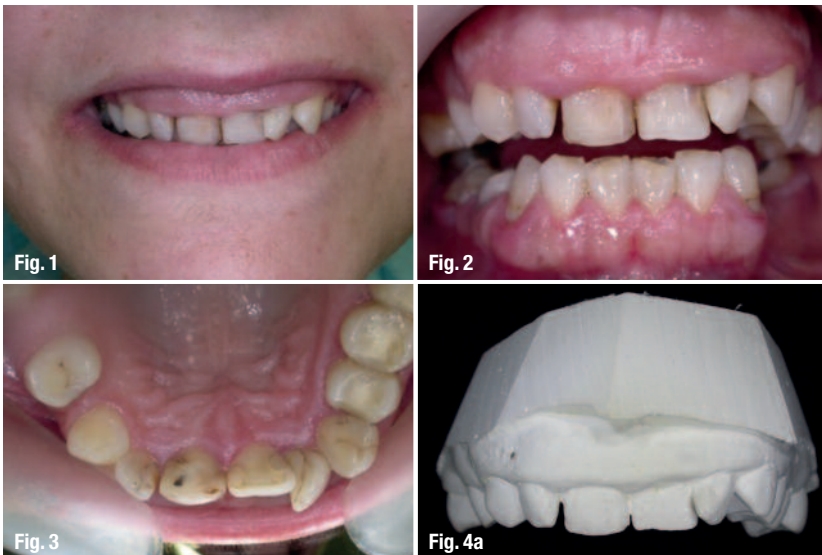The predictability of gingival line levels after crown-lengthening procedures and the healing time required to achieve it are essential factors to consider. The two indications for anterior maxillary crown-lengthening procedures are

1. to increase the amount of labial exposure of the clinical crown;
2. to increase the amount of tooth exposed superior to the bone to prevent impingement of the restoration on the biologic width.

Laser-assisted crown lengthening

Critical to the long-term success of any crown-lengthening procedure—whether accomplished by conventional means or by laser, and whether involving soft-tissue modification alone or in conjunction with osseous surgery—is preservation of biologic

Figs. 1 & 2 A high smile line and the affected outline of the incisal line.
Fig. 3 Problems with teeth #13, 12 and 22, occlusal view.
Figs. 4a & b Asymmetrical gingival line with high lip line.



width.⁷ In order to accomplish this goal, it is necessary to consider the width of the attached gingiva and the location of the underlying alveolar crest to properly define the surgical approach for aesthetic crown lengthening. Assessing the extent of attached gingiva ascertains the relationship between the attached gingiva and the anatomic crown.

In order to determine the location of anatomical landmarks, which will indicate whether there is gingival excess or normal gingival width, and the location of the alveolar crest in relation to the cemento-enamel junction (CEJ), their measurement is required. Transgingival sounding of the alveolar crest determines its relationship to the gingival crest, the CEJ and the mucogingival junction. The surgical treatments to correct defects are based on the values of these parameters.

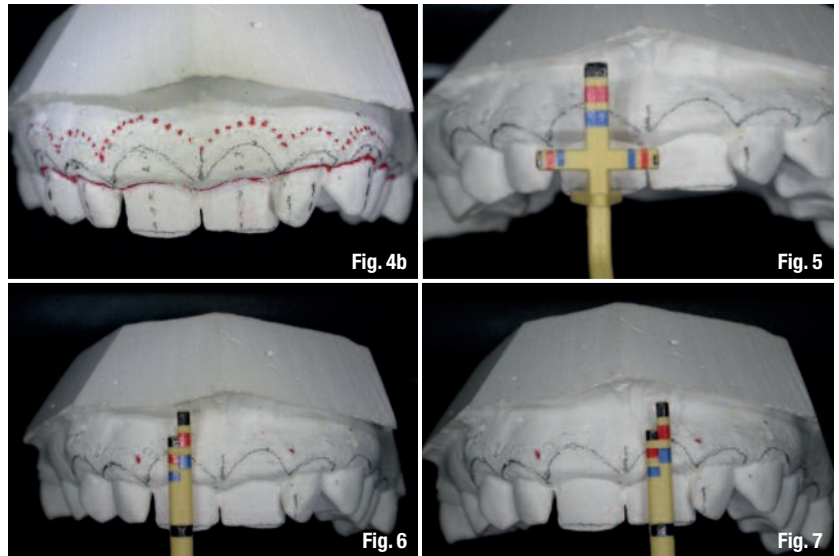
The ability of lasers to perform soft- and hard-tissue crown lengthening has been described in several published reports.⁸⁻¹¹ The use of the Er:YAG laser for gingival and bony recontouring has a significant impact on the way crown lengthening is performed. Since the laser cuts only at the end of the tip, the user has effective control of soft- and hard-tissue resection. When using traditional rotary instruments to perform osseous resection, there is always the risk that their rotation will damage adjacent root surfaces. Additionally, since the surgical laser wound is less traumatic, there is less chance of bony damage due to frictional heat, which is always possible when using rotary instrumentation without proper irrigation. This minimally invasive technology results in less post-operative discomfort and quicker healing of the patient.¹²

Case presentation

A 38-year-old female patient was referred for comprehensive dental treatment. The clinical evaluation revealed a long list of problems. In addition, numerous teeth had undergone root canal treatment that would require endodontic retreatment. One of the patient's desires was to improve the appearance of her smile. The examination was completed and the appropriate diagnostic information was collected, including periodontal and occlusal evaluations. Study models were obtained and mounted with a facebow and centric relation bite records.

Problems identified

1. Active general chronic periodontitis
2. Insufficient endodontic treatment of teeth #44 and 45
3. Insufficient fillings in teeth #18, 17, 12, 11, 21, 22, 23, 24, 25, 26, 38, 37, 33, 43, 44, 45
4. Tooth #27 was to be extracted
5. Missing teeth: #16, 14, 28, 36, 35, 34, 46



6. Missing teeth to be replaced: #16, 14, 34, 35 and 36
7. Poor aesthetics: Gummy smile

Figs. 5–8 Measuring and marking the mid-facial length of the anticipated clinical crown and the length of the biologic crown with Chu's Aesthetic Gauges.

Step-by-step treatment plan

Initial therapy

1. Conventional and Er:YAG laser-assisted treatment of the mild to moderate periodontitis
2. Endodontic treatment and filling
3. Tooth extraction

Basic corrective therapy

1. Implants
2. Er:YAG-assisted crown lengthening in the anterior maxillary region (teeth #13–23) in order to correct the gummy smile

Corrective therapy

1. Prostheses in the retro-canine regions
2. Aesthetic prostheses in the anterior maxillary region (teeth #13–23)

Recall

First, the treatment for correction of the gummy smile was planned. The treatment planning process was initiated by evaluating the position of the maxillary teeth. The photographs show a high smile line and the affected outline of the incisal line (Figs. 1 & 2). The alignment of the teeth from the occlusal view demonstrates the problems with teeth #13, 12 and 22 (Fig. 3).

The occlusal plane of the left posterior teeth required correction in order to allow sufficient interocclusal distance to restore the mandibular left posterior region with two implants in regions #36 and 34 for supporting a small posterior bridge. Therefore, the procedure began with trimming of the incisal edge of the central and lateral incisors. Once the position of the maxillary occlusal plane had been decided, the position of the cervical or gingival line was evaluated. Since

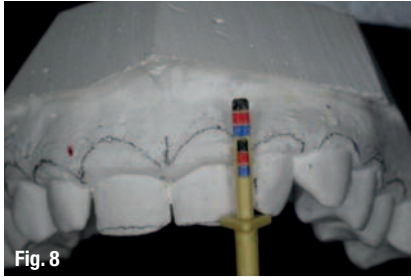


Fig. 8

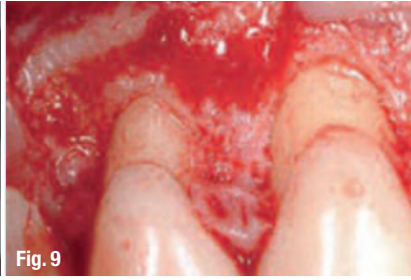


Fig. 9



Fig. 10

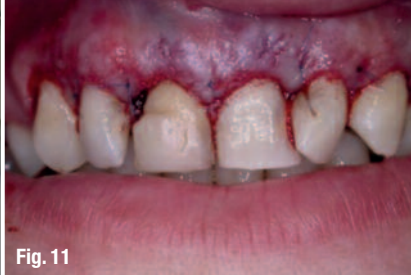

Fig. 11

Fig. 9_Osseous reshaping of the alveolar crest line.

Fig. 10_Reshaping was performed using the LiteTouch Er:YAG laser straight handpiece.

Fig. 11_The mucoperiosteal flap was repositioned and sutured with 6-0 silk sutures, paying particular attention to primary closure of the flap.

there was an asymmetrical gingival line with a high lip line, that is, a gummy smile (Figs. 1 & 4), crown lengthening was planned in order to improve several problems with the patient's smile. Since it had been established that crown lengthening using an erbium laser would be the best treatment option for the patient, the extent of crown lengthening to be performed was determined by evaluating the patient's photographs and a template made from the diagnostic wax-up on stone models of the patient's mouth. The measuring and positioning of the gingival line and bone level were done using Chu's Crown Lengthening Gauge with the Biologic Periogauge tip (Hu-Friedy), which is designed to measure the mid-facial length of the anticipated restored clinical crown and the length of the biologic crown (i.e. from the bone crest to the incisal edge) simultaneously during surgical crown lengthening (Fig. 5).¹³

Fig. 12_Four weeks post-operatively, the final prosthetic reconstruction took place and included crowns on the central and lateral incisors and veneers on the canines.

Measurements can be performed directly on the patient's teeth. After discussing the treatment options, the decision was made to perform crown-lengthening

surgery with an open technique and osseous reshaping. After three to four weeks, the final prosthetic reconstruction would be done.

_Treatment

Before initiating any clinical treatment, a full set of radiographs were taken to determine whether the bone level was at or below the CEJ. Study models and a diagnostic wax-up were then prepared. The procedure began by measuring and marking the mid-facial length of the anticipated clinical crown and the length of the biologic crown with Chu's Aesthetic Gauges (Hu-Friedy; Figs. 5-8).

Performing an external bevel gingivectomy

Once the new free gingival line location had been created, the first step in the process after local anaesthesia was to perform the Er:YAG laser-assisted gingivectomy with the LiteTouch laser (2,940nm; Syneron Dental Lasers) using the straight handpiece. With the tip almost parallel to the root surface, the soft tissue was cut in a sweeping motion from mesial to distal to the level just coronal to the marked points, followed by sloping of the 90-degree gingival edge made during the first cut.

Recontouring the bone

After administering anaesthetic, an incision was made with the laser at the buccal and palatal sides of teeth #13-23 and a vertical incision was not required. A full-thickness mucoperiosteal flap was then reflected. The osseous reshaping of the alveolar crest line (Fig. 9) was performed using the LiteTouch straight handpiece (Fig. 10). The buccal and palatal flaps were lifted and the area was explored for any soft tissue around the neck of the teeth. The soft tissue was ablated using the laser. Vaporisation of soft/granulation tissue (if any) after raising a flap can be achieved efficiently with the Er:YAG laser and there is often no need for hand instruments. The bone was recontoured in a sweeping motion, with the tip moving laterally from mesial to distal following the CEJ. The mucoperiosteal flap was repositioned and sutured with 6-0 silk sutures, paying particular attention to primary closure of the flap (Fig. 11).

The laser operating parameters employed for the various surgical stages were as follows:

- Flap access: wavelength of 2,940nm (Er:YAG), 600µ sapphire tip, soft-tissue mode, contact mode, 100mJ per pulse at 30Hz, and total power of 3W.
- Soft-tissue removal: wavelength of 2,940nm (Er:YAG), 1,300µ sapphire tip, soft-tissue mode, non-contact mode, 200mJ per pulse at 20Hz, and total power of 4W.
- Bone surgery: wavelength of 2,940nm (Er:YAG), 1,300µ sapphire tip, hard-tissue mode, non-contact



Fig. 12

Kurz & bündig

Für ein erfolgreiches Ergebnis mit Langzeitstabilität sind eine genaue Diagnose und die darauffolgende Entwicklung eines umfangreichen Behandlungsplans unabdingbar. Heutzutage können Zahnärzte Restaurationen vornehmen, die in Harmonie mit Lippen, Gesicht, benachbarten Zähnen und einem gesunden Parodontium stehen. Das Aussehen des Zahnfleisches, das die Zähne umgibt, hat großen Anteil an der Frontzahnästhetik. Abweichungen in Symmetrie und Umriss können die erwartete dentale Rehabilitation signifikant beeinflussen.

Eine der häufig verwendeten Methoden zur Erfüllung ästhetischer Anforderungen ist die chirurgische Kronenverlängerung. Diese beinhaltet entweder nur die Entfernung des Zahnfleisches oder die Entfernung von Knochen und Zahnfleisch. Dabei spielt es keine Rolle, welches unterstützende parodontale Gewebe involviert ist. Hauptziel ist es, den Anteil supragingivaler Zahnstruktur für ästhetische und/oder restaurative Zwecke zu erweitern oder zu steigern.

Im vorliegenden Fall wurde eine 38-jährige Patientin mit einer umfangreichen Liste klinischer Probleme vorgestellt. Zahlreiche Zähne wurden bereits einer Wurzelkanalbehandlung unterzogen, die eine endodontische Behandlung erforderten. Die Patientin wollte vor allem wieder ein ansprechendes Lächeln. Basierend auf einem fundierten Behandlungsplan wurde Schritt für Schritt eine umfangreiche Sanierung beginnend bei der laserunterstützten Behandlung einer moderaten Parodontitis, eine endodontische Behandlung, Zahnextraktion, Einsetzung von Implantaten über eine laserunterstützte Kronenverlängerung bis hin zur prothetischen Versorgung vorgenommen.

Wie der vorliegende Fall zeigt, kann eine angemessene Auswahl und die richtige Verwendung eines dentalen Lasers die chirurgische Prozedur für Patient und Doktor stark vereinfachen und ein vorhersehbares Ergebnis liefern. Der Erbium Laser als alternatives Werkzeug für eine Kronenverlängerung stellt dabei für den Patienten eine minimal-invasive Behandlungsoption dar. Nachteilige Nebeneffekte, die mit einer konventionellen Behandlung verbunden sind, können damit minimiert werden. Die chirurgische Kronenverlängerung mit dem Laser geht schnell, ist nicht sehr schwierig und bietet dem Patienten Sicherheit und Komfort.

mode, 200mJ per pulse at 20Hz, and total power of 4W.

Post-operative instructions

The patient was prescribed painkillers to be taken if necessary. Instructions were given to rinse with 0.2% chlorhexidine three times per day, starting the next day for two weeks. The sutures were removed on the seventh day post-operatively, and minor laser reshaping of a few areas on the gingival line was done after three weeks using the LiteTouch (spot size of 0.8mm with tip, soft-tissue mode, non-contact mode, 100mJ per pulse at 20Hz, and total power of 2W).

Four weeks post-operatively, the final prosthetic reconstruction took place and included crowns on the central and lateral incisors and veneers on the canines (Fig. 12). The recall period was set at three months for check-up and professional cleaning.

Conclusion

From this case report and presentation of the Er:YAG laser-assisted crown-lengthening procedure, it can be concluded that the LiteTouch laser with the straight handpiece can be employed as an auxiliary device, and it has been proven to be effective and safe. The

use of the LiteTouch laser for this procedure represents numerous advantages: because the erbium laser is end cutting, collateral tissue damage frequently associated with conventional methods can be prevented; the laser uses a non-contact mode with a water spray for ablating the tissue, thereby minimising the heat generation that could lead to thermal side-effects; the lack of vibrations reduces patient discomfort during use and during post-operative recovery; and stable gingival tissue reduces the likelihood of coronal tissue proliferation or gingival recession after the procedure owing to the minimally invasive technique. Finally, the LiteTouch straight handpiece offers the dentist better and easier handling with 360-degree rotation.

contact

Prof. Dr Ana Minovska, DDS

ETERNAdent
Orce Nikolov 190-1/1
1000 Skopje
Macedonia

aminovska@eternadent.com.mk
www.eternadent.com.mk